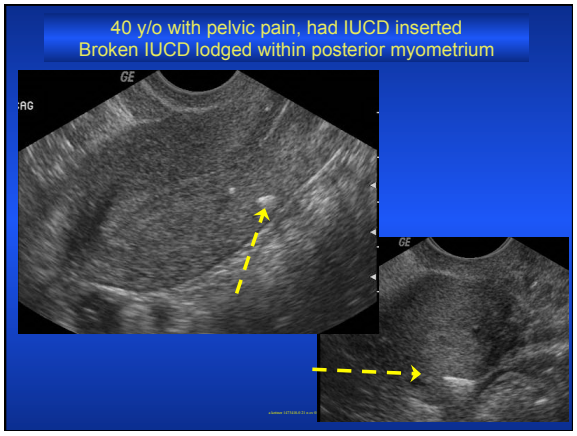
40 y/o with pelvic pain, had IUCD inserted
Broken IUCD lodged within posterior myometrium

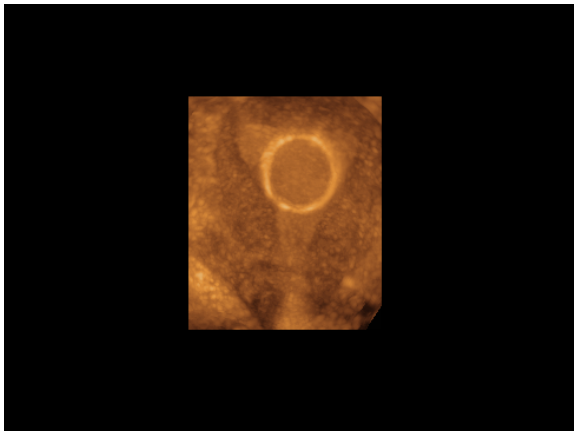

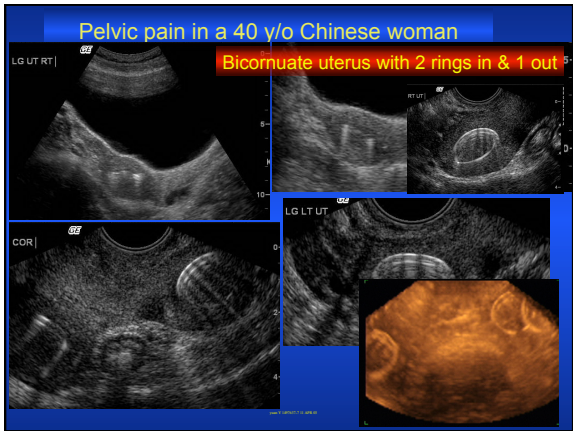
Pelvic pain in a 40 y/o Chinese woman
Bicornuate uterus with 2 rings in & 1 out
LG UT RT
LG LT UT
COR

Pelvic pain in a 40 y/o Chinese woman
Bicornuate uterus with 2 rings in & 1 outside


Types of IUCD's
Put in postpartum to prevent pregnancy

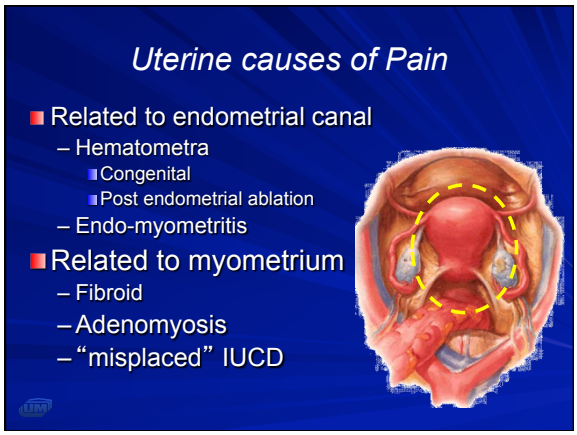
Uterine causes of Pain
Related to endometrial canal
– Hematometra
Congenital
Post endometrial ablation
– Endo-myometritis
Related to myometrium
– Fibroid
– Adenomyosis
– "misplaced" IUCD

When you have pelvic pain
IS THIS the way you feel?

Or do you just sit back and cope?